

Multicentric T-cell Lymphoma Associated with Feline Leukemia Virus infection in a Captive Namibian Cheetah (*Acinonyx jubatus*)

Laurie Marker,¹ Linda Munson,^{2*} Peter A. Basson,³ and Sandra Quackenbush^{4,5} ¹ Cheetah Conservation Fund, Otjiwarongo, Namibia; ² Department of Pathology, Microbiology and Immunology, School of Veterinary Medicine, University of California, Davis, California, 95616, USA; ³ Regional Veterinary Laboratory, Division of Veterinary Services, Grootfontein, Namibia; ⁴ Department of Microbiology and Immunology, Cornell University, Ithaca, New York 14853, USA; ⁵ Current address: Department of Molecular Biosciences, University of Kansas, Lawrence, Kansas 66045, USA; * Corresponding author (email: lmunson@ucdavis.edu)

ABSTRACT: This case report describes a multicentric lymphoma in a 4 yr old female wild-born captive cheetah (*Acinonyx jubatus*) in Namibia after being housed in an enclosure adjacent to a feline leukemia virus (FeLV) infected cheetah that had previously been in contact with domestic cats. The year prior to the onset of clinical signs, the wild-born cheetah was FeLV antigen negative. The cheetah subsequently developed lymphoma, was found to be infected with FeLV, and then rapidly deteriorated and died. At necropsy, the liver, spleen, lymph nodes, and multiple other organs were extensively infiltrated with neoplastic T-lymphocytes. Feline leukemia virus DNA was identified in neoplastic lymphocytes from multiple organs by polymerase chain reaction and Southern blot analysis. Although the outcome of infection in this cheetah resembles that of FeLV infections in domestic cats, the transmission across an enclosure fence was unusual and may indicate a heightened susceptibility to infection in cheetahs. Caution should be exercised in holding and translocating cheetahs where contact could be made with FeLV-infected domestic, feral, or wild felids.

Key words: *Acinonyx jubatus*, case report, cheetah, feline leukemia virus, lymphoma, Namibia, T-lymphocyte.

The cheetah (*Acinonyx jubatus*) population in Namibia principally resides on farmlands and continues to be endangered by human activities. High numbers of cheetahs have been captured and removed by farmers as perceived threats to livestock and game (Marker-Kraus, 1996). Trapped cheetahs are often held in groups on farms where infectious agents are easily transmitted and may be acquired from unvaccinated domestic and feral cats. Because captured cheetahs may stock wildlife reserves in southern Africa or provide new founder animals for captive breeding programs, the acquisition of domestic feline

viruses by wild cheetahs during holding and translocation is a cause of concern.

Feline leukemia virus (FeLV) was first isolated in 1964 from domestic cats with lymphoma or myeloid leukemia and now infects only a small proportion of healthy cats (Cotter, 1998). The prevalence of FeLV-associated lymphomas has declined in the United States due to widespread testing and control measures (Cotter, 1998). Feline leukemia virus is typically transmitted among domestic cats through saliva or blood from grooming, fighting, or shared environments. Feline leukemia virus infection has only rarely been reported in captive wild felids, including one of 21 cheetahs in a collection. (Efron et al., 1977; Douglass, 1979; Rusheed and Gardner, 1981; Meric, 1985; Briggs and Ott, 1986; Boid et al., 1991; Jessup et al., 1993). Infection has not been associated with clinical disease except in one wild cougar (*Felis concolor*) that had lymphoid hyperplasia and anemia (Jessup et al., 1993).

The Cheetah Conservation Fund (CCF) near Otjiwarongo, Namibia, is a non-government organization with educational, scientific, and conservation programs aimed at preserving a healthy cheetah population in Namibia. Cheetah Conservation Fund often houses wild-caught cheetahs for rehabilitation and translocation and cares for orphan cheetahs. A wild-caught, orphan, female cheetah (Cheetah #1) was hand-raised and housed at CCF from 1991-95. The cheetah had been housed alone since 5 wks of age at a facility with no domestic cats, then moved to CCF

when 8 mo old, where it was housed alone until its death.

In December 1993, a wild-caught, captive-raised 2 yr old male cheetah (Cheetah #2) was confiscated from a private facility by a local authority and placed at CCF. The originating facility also housed two wild-caught cheetahs (Cheetah #3 and Cheetah #4) that were 18 mo and 4 yr old and had a large number of feral domestic cats. Prior to confiscation, Cheetah #2 was attacked by Cheetah #4 who was housed in an adjacent pen, resulting in deep lacerations and puncture wounds. In February 1994, Cheetah #3 became ill, so serum was tested from Cheetah #3 and #4 for FeLV antigens with an antigen detection enzyme linked immunosorbent assay (ELISA; Golden Vet Lab, Johannesburg, South Africa). Both animals were positive for FeLV antigens. Cheetah #3 subsequently died, but the cause of death was not determined because no necropsy was performed.

After moving to CCF in December 1993, Cheetah #2 was housed in a pen adjacent to Cheetah #1 with only a single wire-mesh fence separating the enclosures. Although food dishes and water sources were not shared, the cheetahs often had aggressive interactions across the fence line. Because of the positive FeLV tests in Cheetahs #3 and #4 and history of fighting between Cheetahs #2 and #4, serum was collected in February 1994 at CCF from Cheetahs #1 and #2 for FeLV antigen testing. The ELISA test was positive in Cheetah #2 and negative in Cheetah #1. The positive FeLV antigen tests in Cheetahs #2 and #4 were confirmed with an ELISA performed at the Washington Animal Disease Diagnostic Lab (WADDL, Pullman, Washington, USA); serum was not available from Cheetah #3 for retesting.

In January 1995, Cheetah #1 became lethargic, irritable, anorectic, and appeared to have lost weight. A minimal physical examination was performed in February 1995 by CCF staff who could handle the

cheetah. The cheetah was painful on palpation of the right cervical region, but the only abnormality noted was a large tick embedded in the skin. Two weeks later, the cheetah developed ptialism, marked bilateral lymphadenopathy in the facial and neck regions, polydipsia, and pica. At the time, more intensive diagnostic procedures were not possible, so antibiotic treatment was given empirically. First, the animal was treated with oral tetracycline (Upjohn, Kalamazoo, Michigan, USA; 625 mg per os, three times per day), then changed to doxycycline (Medpet, Pty, Johannesburg, South Africa; 300 mg, per os, twice per day) for suspected rickettsial disease. Despite treatment, the cheetah developed bilateral facial swelling in the maxillary region, bilateral ptosis, and wheezing over the next few days.

In March 1995, the cheetah was anesthetized with tiletamine HCl and zolazepam HCl (Telazol®; Warner Lambert, Ann Arbor, Michigan; 4 mg/kg, intramuscular) for evaluation. The cheetah was febrile (40.8 C) with bilateral, symmetrical facial edema. Cervical, prescapular, and popliteal lymph nodes were enlarged and firm, and there was mild splenomegaly. Aspirates of lymph nodes had large atypical lymphocytes that were interpreted as lymphoblastic lymphoma. Values from complete hematology and serum chemistry analyses were within normal reference ranges. An ELISA test for FeLV antigens was positive. Despite supportive treatment, the cheetah's condition continued to deteriorate, and she died 3 days later.

At necropsy, there was marked enlargement of all lymph nodes, splenomegaly, and hepatomegaly. Histopathologic findings included effacement of lymph node architecture and marked infiltration of hepatic portal areas and splenic sinusoids by malignant lymphocytes with both large and small cell morphology. Malignant lymphocytes were also present in the interstitium of the kidney, lung, tonsil, salivary gland, thyroid, trachea, and bone marrow. Immunohistochemical stains for B and

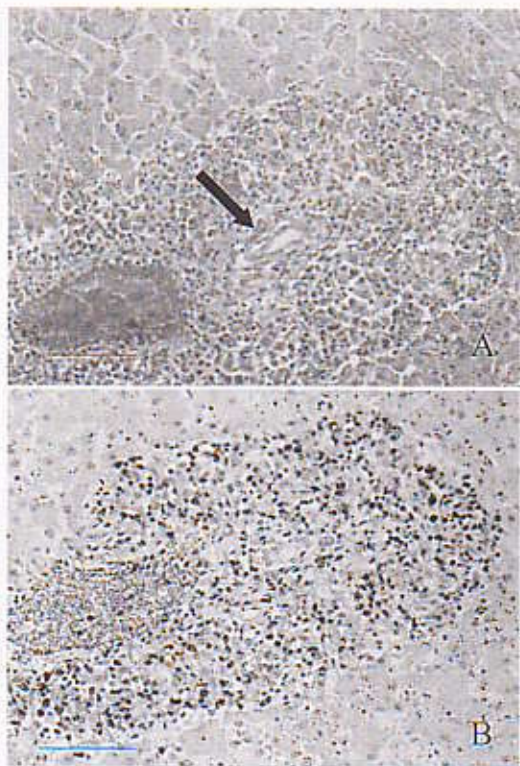


FIGURE 1. Liver of a cheetah with multicentric lymphoma. Portal areas are markedly expanded with neoplastic lymphocytes. A) Hematoxylin and eosin stain. Bile duct (arrow) and portal veins are surrounded by neoplastic cells. B) Immunohistochemical stain for CD3 (T-cells). The neoplastic cells are positive for the T-cell marker. Bar=75 μ m.

T cell markers were performed on formalin-fixed, paraffin-embedded sections using monoclonal antibodies previously validated for use in cheetahs (Terio, 2000). The neoplastic cells were CD3 positive (Fig. 1) and CD79A and CD45R negative. The final diagnosis was multicentric T-cell lymphoma.

To determine if the neoplastic lymphocytes contained FeLV, DNA was extracted and subjected to polymerase chain reaction (PCR) using primers that amplify a 155-bp region of the SU gene from exogenous FeLV subgroup A. DNA was isolated from lymph node, liver, spleen, and lung, and PCR and Southern blot analysis for FeLV were performed as described (Quackenbush et al., 1989, 1996). Briefly,

1 μ g of DNA was amplified by PCR. The PCR mixture consisted of 20 mM Tris-HCl (pH 8.4), 50 mM KCl, 2 mM MgCl₂, a 125 μ M concentration of each dNTP, 10 pmol of each primer (TR1-5'AATGTAAAAC-ACGGGGCA3', Q1-5'CCCATCTTGT-GCCCCCTCCA3'), and 2.5 units of *Taq* DNA polymerase (Gibco BRL, Grand Island, New York, USA) in a total volume of 100 μ l. All samples were denatured at 94 C for 5 min and then each amplification consisted of 30 sec at 94 C, 20 sec at 57 C, 20 sec at 72 C for 35 cycles, followed by one cycle at 72 C for 5 min. Fifteen microliters of the amplified product was separated on a 2% agarose gel. For Southern blot analysis, total cellular DNA (10 μ g) was digested with *Kpn*I, separated through a 1% agarose gel, and transferred to nitrocellulose. The blot was crosslinked with ultraviolet light and hybridized with the exogenous FeLV-specific probe (exU3). The FeLV exU3 probe identifies a 250-bp sequence in the unique region of the long terminal repeat of exogenous feline retroviruses only (Mullins et al., 1980, 1981).

All neoplastic tissues from Cheetah #1 contained the FeLV sequence (Fig. 2). DNA isolated from the spleen of the control animals was negative by PCR for FeLV. Southern blot analysis of *Kpn*I digested DNA and hybridization with the exU3 LTR-specific probe demonstrated the presence of an internal virus band of 3.6 kb in all tissues from Cheetah #1. A pattern of clonal viral integration was also revealed in these tissues suggesting a clonal proliferation and systemic dissemination of virus-infected cells.

This is the first confirmed case of FeLV-associated lymphoma in a non-domestic felid. The source of FeLV was presumed to be Cheetah #2 that was housed in close proximity to Cheetah #1 and had been exposed to domestic cats at its previous location. Unfortunately, no confirmatory tests were performed on the domestic cats, although FeLV infections do occur in cats in Namibia. The means of transmission

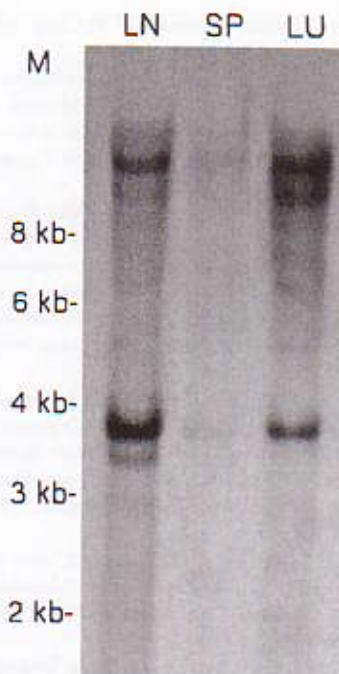

FIGURE 2. Identification of feline leukemia virus in tissues from a cheetah with lymphoma. Total cellular DNA was extracted and analyzed by Southern transfer and hybridization using the FeLV exU3 probe. LN, SP, and LU correspond to lymph node, spleen, and lung, respectively. The relative molecular mass of DNA (M) is shown in kb pairs. The FeLV internal virus band migrates at 3.65 kb.

from Cheetah #2 to Cheetah #1 is assumed to have been via saliva through the enclosure fence. Food dishes, direct physical contact, and other traditional means of FeLV transmission were unlikely, because preventive hygiene practices were in use. The animals were housed in adjacent enclosures because the risk of transmission was thought to be low without direct contact and with known viral lability.

Although the outcome of infection in this cheetah resembles that of FeLV infections in domestic cats (Cotter, 1998), the transmission across an enclosure fence was unusual and may indicate a heightened susceptibility to infection in cheetahs. Cheetahs are thought to be particularly susceptible to some viral infection because of reduced levels of MHC diversity (O'Brien et al., 1985; Johnson et al., 2001).

However, they tend to develop abnormally exuberant immune responses to common pathogens, rather than appearing immunosuppressed (Evermann et al., 1988; Heeney et al., 1990; Junge et al., 1991; Munson, 1993; Munson et al., 1998). It is possible that stress from several recent environmental changes in the management of Cheetah #1 predisposed this animal to infection (Cotter, 1998). Two months prior to the onset of illness, Cheetah #1 was moved to a new location, Cheetah #2 was removed from the adjacent enclosure, and the rainy season began. However, baseline fecal corticoids were being measured in Cheetah #1 during these preceding months and significant elevations were not noted until 2 days prior to death (K. Terio, pers. comm.). Canine distemper virus (CDV) antibodies were detected in Cheetah #1 in early 1994 concurrent with seroconversion in other cheetahs in this region. It is possible that immunosuppression from recent CDV infection permitted FeLV viremia to progress to malignancy in this case (Cotter, 1998).

Over the past 10 yr, CCF has tested over 100 wild Namibian cheetahs for FeLV, and no positive animals have been detected (Munson and Marker, unpubl. data). Additionally, over 100 cheetahs in captivity in Namibia were tested of which only four animals (those in this report) were FeLV antigen-positive. These data indicate that FeLV is not endemic in wild cheetah populations in Namibia, but that cheetahs are susceptible to FeLV infection and its consequences. This case report also provides further evidence that wild populations could be adversely affected by proximity to domestic cats. Caution should be exercised in holding and translocating cheetahs where contact could be made with FeLV-infected domestic or feral felids. Also, when feasible, wild cheetahs that have been exposed to domestic cats should be tested for FeLV before release.

The authors thank H. Scherer, D. Kraus, S. P. DeVincent, S. Hurlbut, and

R. Papendick for their contributions to this case. Support for this investigation was provided by the Cheetah Conservation Fund, the University of Tennessee, and Cornell University (NIH grant ROI RR12544, James W. Casey). All tissue samples were collected in full compliance with specific Federal Fish and Wildlife permits (Convention on International Trade in Endangered Species of Wild Fauna and Flora [CITES]; Endangered and Threatened Species) issued to the National Cancer Institute, National Institutes of Health (principal officer S. J. O'Brien) by the U.S. Fish and Wildlife Service of the U.S. Department of the Interior, as well as CITES permit issued to the Cheetah Conservation Fund (principal officer L. Marker) from the Namibian Ministry of Environment and Tourism.

LITERATURE CITED

- BOID, R., S. MCOBIST, T. W. JONES, N. EASTERBEE, A. L. HUBBARD, AND O. JARRETT. 1991. Isolation of FeLV from a wild felid (*Felis silvestris*). *Veterinary Record* 128: 256.
- BRIGGS, M. B., AND R. L. OTT. 1986. Feline leukemia virus in a captive cheetah and the clinical and antibody response of six captive cheetahs to vaccination with a subunit feline leukemia virus vaccine. *Journal of the American Veterinary Medical Association* 189: 1197-1199.
- COTTER, S. M. 1998. Feline viral neoplasia. In *Infectious diseases of the dog and cat*, 2nd Edition, C. E. Green (ed.), W.B. Saunders Company, Philadelphia, Pennsylvania, pp. 71-84.
- DOUGLASS, E. M. 1979. Lymphosarcoma and blockage of the biliary duct in an African lion (*Panthera leo*). *Veterinary Medicine Small Animal Clinician* 74: 1637-1641.
- EFFRON, M., L. GRINER, AND K. BENIRSCHKE. 1977. Nature and rate of neoplasia found in captive and wild animals, birds and reptiles. *Journal of the National Cancer Institute* 59: 185-198.
- EVERMANN, J. F., J. HEENEY, M. ROELKE, AND S. J. O'BRIEN. 1988. Biological and pathological consequences of feline infectious peritonitis virus in captive cheetahs. *Archives of Virology* 102: 155-172.
- HEENEY, J. F., J. F. EVERMANN, A. J. MCKIERNAN, L. MARKER-KRAUS, M. E. ROELKE, M. BUSH, D. E. WILDT, D. G. MELTZER, L. COLLY, J. LUCAS, V. J. MANTON, T. CARO, AND S. J. O'BRIEN. 1990. Prevalence and implications of coronavirus infections of captive and free-ranging cheetahs (*Acinonyx jubatus*). *Journal of Virology* 64: 1964-1972.
- JESSUP, D. A., C. PETTAN, L. J. LOWENSTINE, AND N. C. PEDERSEN. 1993. Feline leukemia virus infection and renal spirochetosis in a free-ranging cougar (*Felis concolor*). *Journal of Zoo and Wildlife Medicine* 24: 73-79.
- JOHNSON, W. E., E. EIZIRIK, M. ROELKE-PARKER, AND S. J. O'BRIEN. 2001. Applications of genetic concepts and molecular methods to carnivore conservation. In *Carnivore conservation*, J. L. Gittleman, S. M. Funk, D. W. Macdonald and B. K. Wayne (eds.), Cambridge University Press, Cambridge, UK, pp. 335-358.
- JUNGE, R. E., R. E. MILLER, W. J. BOEVER, G. SCHERBA, AND J. SUNDBERG. 1991. Persistent cutaneous ulcers associated with feline herpes virus type 1 infection in a cheetah. *Journal of American Veterinary Medical Association* 198: 1057-1058.
- MARKER, L., D. KRAUS, D. BARNETT, AND S. HURIBUT. 1996. Cheetah survival on Namibian farmlands. Cheetah Conservation Press, Windhoek, Namibia, pp. 1-85.
- MERIC, S. M. 1985. Suspected feline leukemia virus infections and pancytopenia in a western cougar. *Journal of the American Veterinary Medical Association* 185: 1390-1391.
- MULLINS, J. I., J. W. CASEY, M. NICHOLSON, AND N. DAVIDSON. 1980. Sequence organization of feline leukemia virus DNA in infected cells. *Nucleic Acids Research* 8: 3287.
- , ———, ———, K. B. BURCK, AND N. DAVIDSON. 1981. Sequence arrangement and biological activity of cloned feline leukemia virus proviruses from a virus-productive human cell line. *Journal of Virology* 38: 688-703.
- MUNSON, L. 1993. Diseases of captive cheetahs (*Acinonyx jubatus*): Results of the Cheetah Research Council pathology survey, 1989-1992. *Zoo Biology* 12: 105-124.
- , J. W. NESBIT, D. G. A. MELTZER, L. P. COLLY, L. BOLTON, AND N. P. J. KRIEK. 1999. Diseases of captive cheetahs (*Acinonyx jubatus*): A 20 year retrospective survey. *Journal of Zoo and Wildlife Medicine* 30: 342-347.
- O'BRIEN, S. J., M. E. ROELKE, L. MARKER, A. NEWMAN, C. A. WINKLER, D. MELTZER, L. COLLY, J. F. EVERMANN, M. BUSH, AND D. E. WILDT. 1985. Genetic basis for species vulnerability in the cheetah. *Science* 227: 1428-1434.
- QUACKENBUSH, S. L., G. A. DEAN, J. I. MULLINS, AND E. A. HOOVER. 1996. Analysis of FeLV-faids provirus burden and productive infection in lymphocyte subsets in vivo. *Virology* 223: 1-9.
- , J. I. MULLINS, AND E. A. HOOVER. 1989. Colony forming T-lymphocyte deficit in the development of feline retrovirus induced immunodeficiency syndrome. *Blood*: 509-516.

RUSHEED, S., AND M. B. GARDNER. 1981. Isolation of feline leukemia virus from a leopard cat cell line and search for retrovirus in wild Felidae. *Journal of the National Cancer Institute* 67: 929-933

Helicobacter-associated gastritis in cheetahs (*Acinonyx jubatus*). Ph.D. Dissertation, University of California, Davis. 226 pp.

TERIO, K. A. 2000. Potential mechanisms underlying

Received for publication 29 September 2002.